

Thunderstorms and iPods — Not a Good iDea

TO THE EDITOR: The potential for permanent hearing loss due to prolonged use of personal stereo equipment, such as portable compact-disk or MP3 players, at high decibel levels has been well described in the literature.¹ We have recently become aware of an additional, albeit uncommon, hazard associated with the use of such devices.

A 37-year-old man was brought to the emergency department at our hospital. He had been jogging in a thunderstorm, listening to his iPod, when an adjacent tree was struck by lightning. Witnesses reported that he was thrown approximately 8 ft (2.4 m) from the tree.

The patient had second-degree burns on his chest and left leg. In addition, two linear burns extended along his anterior chest and neck to the sides of his face, terminating in substantial burns in the external auditory meatus bilaterally, corresponding to the positions of his earphones at the time of the lightning strike. Both of his tympanic membranes were ruptured, and he had a severe conductive hearing deficit. He also had a mandibular fracture. Computed tomography of the mandible (Fig. 1A) and of the temporal bones showed bilateral dislocation of the incudomalleolar joints (Fig. 1B and 1C). Internal fixation of the mandibular fractures was performed and the perforations of the tympanic membranes were managed with the use of perichondrial grafting.

Although people may be struck directly by lightning, it is more common for the lightning to jump to a person from a nearby object, such as a tree — a phenomenon known as a side flash.² Opisthotonic muscle contraction may project the

victim some distance, leading to further injury from blunt trauma. Because of the high resistance of skin, the lightning is often conducted over the outside of the body (an effect known as a flash-

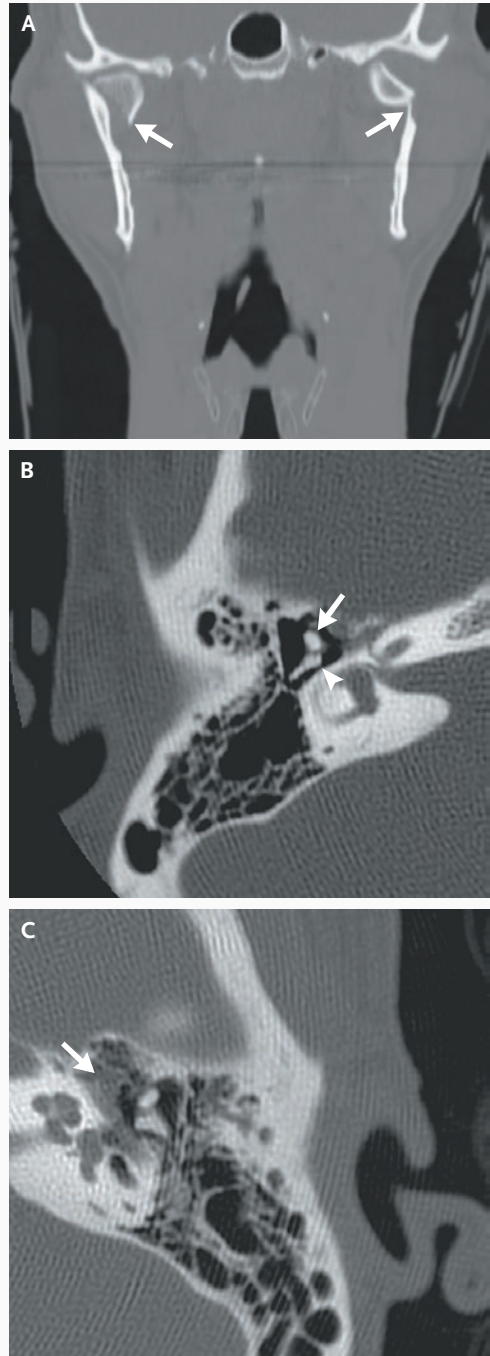


Figure 1. Computed Tomographic Scan of the Mandible and Temporal Bones in the Patient.

A coronal image of the mandible (Panel A) shows bilateral fractures and dislocations of the condylar necks (arrows). A transverse image of the right middle ear (Panel B) shows dislocation of the incudomalleolar joint, with the head of the malleus (arrow) lying lateral to its expected articulation with the body of the incus (arrowhead); normally, these ossicles have an “ice-cream cone” appearance on transverse images. Similar ossicular dislocation is shown in the left middle ear (Panel C); in addition, abnormal soft tissue in the epi-tympanic recess (arrow) indicates the presence of hemorrhage.

over); however, sweat and metallic objects in contact with the skin can disrupt the flashover, leading to the internal flow of current. Although the use of a device such as an iPod may not increase the chances of being struck by lightning,³ in this case, the combination of sweat and metal earphones directed the current to, and through, the patient's head. The mandibular fractures were probably caused by muscle contraction, since there were no external signs of injury to the face. The perforations of the tympanic membranes occurred as a result of the sudden heating and expansion of air around the current, leading to pressure waves. Perforations are commonly seen in patients who have been struck by lightning,⁴ although ossicular injuries appear to be rare.⁵

Eric J. Heffernan, M.B.

Peter L. Munk, M.D.

Luck J. Louis, M.D.

Vancouver General Hospital
Vancouver, BC V5Z 1M9, Canada
ejheffernan@eircom.net

1. Fligor BJ, Cox LC. Output levels of commercially available portable compact disc players and the potential risk to hearing. *Ear Hear* 2004;25:513-27.
2. Mason AD, Crockett RK. When lightning strikes: a case report and review of the literature. *Int Paediatr* 2000;15:173-8.
3. Farragher RM. Injury from lightning strike while using mobile phone: statistics and physics do not suggest a link. *BMJ* 2006;333:96.
4. Glunčić I, Roje Z, Glunčić V, Poljak K. Ear injuries caused by lightning: report of 18 cases. *J Laryngol Otol* 2001;115:4-8.
5. Meriot P, Veillon F, Garcia JF, et al. CT appearances of ossicular injuries. *Radiographics* 1997;17:1445-54.

Correspondence Copyright © 2007 Massachusetts Medical Society.

INSTRUCTIONS FOR LETTERS TO THE EDITOR

Letters to the Editor are considered for publication, subject to editing and abridgment, provided they do not contain material that has been submitted or published elsewhere. Please note the following:

- Letters in reference to a *Journal* article must not exceed 175 words (excluding references) and must be received within 3 weeks after publication of the article. Letters not related to a *Journal* article must not exceed 400 words. All letters must be submitted over the Internet at <http://authors.nejm.org>.
- A letter can have no more than five references and one figure or table.
- A letter can be signed by no more than three authors.
- Financial associations or other possible conflicts of interest must be disclosed. (Such disclosures will be published with the letters. For authors of *Journal* articles who are responding to letters, this information appears in the published articles.)
- Include your full mailing address, telephone number, fax number, and e-mail address with your letter.

Our Web site: <http://authors.nejm.org>

We cannot acknowledge receipt of your letter, but we will notify you when we have made a decision about publication. Letters that do not adhere to these instructions will not be considered. Rejected letters and figures will not be returned. We are unable to provide prepublication proofs. Submission of a letter constitutes permission for the Massachusetts Medical Society, its licensees, and its assignees to use it in the *Journal's* various print and electronic publications and in collections, revisions, and any other form or medium.